

Evidence-Based Medicine: Face Lift

Brian M. Derby, M.D.
Mark A. Codner, M.D.

Sarasota, Fla.; and Atlanta, Ga.



American Board of
Plastic Surgery
ABMS MOC*

Learning Objectives: After studying this article, the participants should be able to: 1. Describe pertinent surgical anatomy relevant to safe and effective face-lifting techniques. 2. Identify key aspects of facial aging. 3. Incorporate risk-reduction strategies during preoperative assessment. 4. Tailor their approach to face lifting based on patient anatomy. 5. Identify and treat complications after face-lift surgery. 6. Incorporate use of valid patient outcomes assessment tools in their practice to facilitate standardized outcomes reporting in the face-lift literature.

Summary: Treating the aged face requires an understanding of bone and soft-tissue anatomy, including the analogous lamellar layers of the face and neck, and the techniques designed to restore youthful skin tone and facial contours. Although volume restoration with fillers is effective for restoring youthful facial contours, the power of face lifting is unmatched in its ability to rejuvenate a sagging facial shape. Standard face-lifting techniques are described, along with the authors' preferred approach, supplemented by video demonstration of the high-superficial musculoaponeurotic system technique. Complications, along with their prevention and treatment, are reviewed. Currently available comparative studies of face-lifting outcomes consider surgeon opinion and post-operative complications rates. A valid, standardized, patient-reported outcome tool, the FACE-Q, has been available since 2010, and should be a component of any comparative discussion of face-lifting techniques in the future. (*Plast. Reconstr. Surg.* 139: 151e, 2017.)

EPIDEMIOLOGY

The American Society of Plastic Surgeons reported that 133,320 face lifts were performed in 2013, up 6 percent from 2012, making face lifts the fifth most popular cosmetic surgery procedure.¹

AGING AND PERTINENT FACIAL ANATOMY

“A young face is not an old face with tight cheek skin.”² Compartments of fat lose volume in time, and deflated facial skin (found superficial to facial spaces) droops across grooves (that outline these spaces) in regions of ligamentous density.³⁻⁵ Previous authors have outlined five superficial and two deep facial fat compartments.⁶ The curves and fullness of youth ultimately give way to the deflated and wrinkled appearance of aging. Restoring aesthetic facial anatomy considers tissue repositioning and volume replacement in the middle to upper thirds of the face, along with volume removal in

the neck and jowls, where lower facial third radial expansion occurs (Fig. 1).^{2,7-11} Volume loss also occurs in skin and bone.

The remaining anatomical discussion will focus on a three-dimensional appreciation of the facial nerve in areas of potential risk for division, the great auricular nerve, the facial spaces, and an update on facial ligamentous anatomy since the writing of the last Maintenance of Certification article.

Disclosure: Dr. Derby has no financial information to disclose. Dr. Codner receives direct, ongoing funding that is used for the purpose of supporting research project expenses, has a consulting relationship with Mentor Corporation (Santa Barbara, Calif.) and Ulthera, Inc. (Mesa, Ariz.), and receives royalties for books published by Quality Medical Publishing and Elsevier.

Supplemental digital content is available for this article. Direct URL citations appear in the text; simply type the URL address into any Web browser to access this content. Clickable links to the material are provided in the HTML text of this article on the Journal's website (www.PRSJournal.com).

From the Sarasota Plastic Surgery Center; and Mark Codner M.D. Plastic Surgery.

Received for publication February 25, 2015; accepted August 25, 2015.

Copyright © 2016 by the American Society of Plastic Surgeons

DOI: 10.1097/PRS.0000000000002851

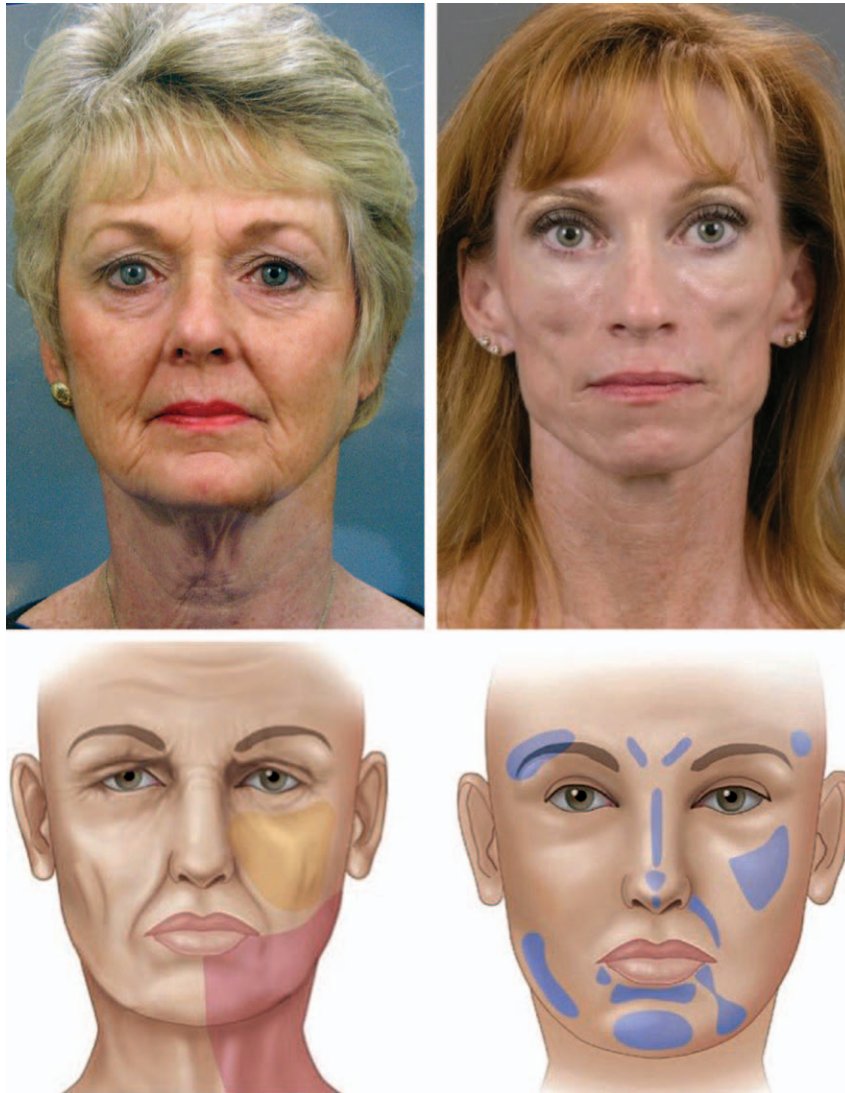

Fig. 1. (Above, left) Radial expansion of the lower third of the face amenable to soft-tissue repositioning. (Above, right) Volume loss of the middle and upper thirds of the face suited to volume restoration, rather than soft-tissue repositioning. (Below) Diagrammatic representation of (red) zones that respond well to soft-tissue repositioning and (blue) zones that respond well to soft-tissue filling.

Facial Nerve

The two-dimensional trajectories of the temporal and marginal mandibular branches of the facial nerve are well documented.¹²⁻¹⁴ Multiple studies have evaluated the two-dimensional course of the temporal branch along a line 0.5 cm below the tragus to a point 1.5 cm above the lateral brow.¹⁵⁻²⁰ These branches are at greatest risk for injury in the temporoparietal, preparotid, and mandibular angle regions.¹⁵

A thorough understanding of three-dimensional facial nerve anatomy, relative to the lamellar facial planes, makes sub-superficial musculoaponeurotic system (SMAS) dissections far less

imposing.²¹ The SMAS is to the temporoparietal fascia what the parotid-masseteric fascia is to the superficial layer of the deep temporal fascia. All fascial layers are adherent at the arch. The adherence extends 2 to 3 cm above the arch as the “inferior temporal septum.”²¹ The nerve courses deep to the adherence and superficial to the periosteum at the arch level. It remains deep and protected by the parotid-masseteric fascia for 2 to 3 cm above the arch (Fig. 2).^{16,22} These principles explain why temporal branch injuries do not occur with careful division of the SMAS above the arch in the high-SMAS technique, and have not occurred in over 930 face lifts performed by the senior author (M.A.C.).

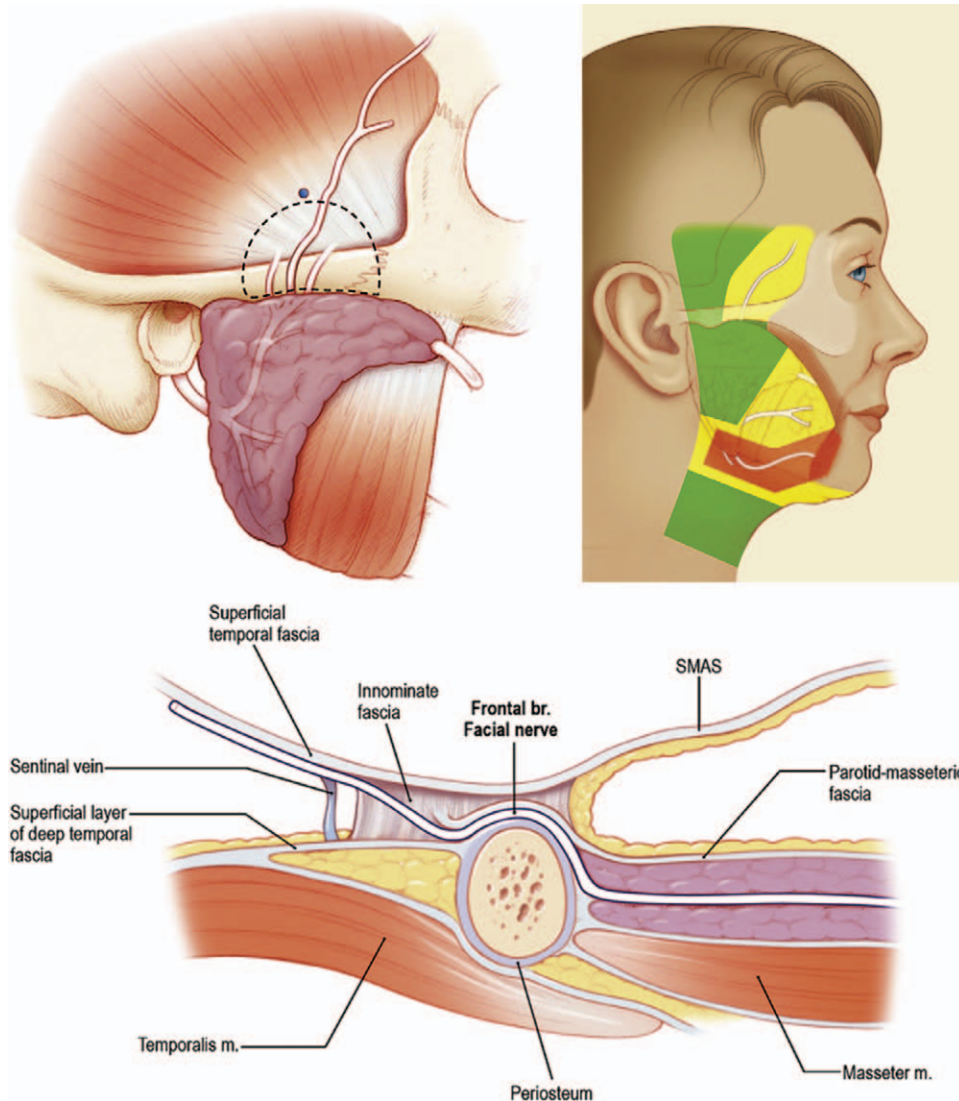


Fig. 2. (Above, left) The trajectory of the temporal branch is demonstrated. Note that the “singular” temporal branch divides into two or three branches across the arch. The *dotted line* depicts the area of superficial and deep fascial adherence, known as the inferior temporal septum. The adherence extends 2 to 3 cm above the arch. The *blue dot* depicts the sentinel vein. (Below) As the nerve crosses the arch, it remains deep to the parotid-masseteric fascia, which blends with the fibroareolar innominate fascia. The nerve transitions from its protected location, deep to the parotid-masseteric fascia to its location on the deep aspect of the temporoparietal fascia, 2 to 3 cm above the arch. (Above, right) A zone extending anteriorly from the mandibular angle to the oral commissure, 1 cm above and 2 cm below the mandibular border, defines the area requiring extreme diligence in dissection deep to the platysma and SMAS to avoid marginal mandibular branch injury. This zone also correlates with the location of greatest risk of injury to the cervical branch. (Reprinted from Owsley JQ, Agarwal CA. Safely navigating around the facial nerve in three dimensions. *Clin Plast Surg.* 2008;35:469–477, with permission from Elsevier.)

The course of the marginal mandibular nerve follows an “80/20 rule.”^{13,14,23} After exiting the parotid, and while posterior to the facial vessels, the marginal mandibular branch is found above the mandibular border in 80 percent of specimens and 1 to 3 cm below the border in 20 percent. It typically exits the inferior edge of the parotid gland

at the level of the mandibular angle, and remains safely deep to the parotid-masseteric fascia and deep fascia of the masseter along its anteriorly directed course.²¹ In the less likely event that it exits inferior to the mandibular border, it runs anteriorly over the digastric muscle and capsule of the submandibular gland, and then superficially, to enter the buccal

Downloaded from http://journals.lww.com/plasreconsurg by RZUSYSRlyqZg+J5ivYovV6s6tG+hNOVYjTYC2t5u bZ2Mw+4Nk6awDKbkfrn0CBSWBtZvol.4I4IGijuznd6kOqeaPqdTYzTrn66446mqQhYZE8w20wLayDv4K55f5imjy9p230= on 11/06/2023

space at the anteroinferior border of the masseter muscle (deep to the platysma) (Fig. 2).

Great Auricular Nerve

The great auricular nerve is the most commonly injured nerve in face lifting. It derives from the C2/C3 spinal nerve roots, and traverses the posterior triangle of the neck before crossing the posterior border of the sternocleidomastoid approximately 6.5 cm below the external auditory canal. It then runs parallel and posterior to the external jugular vein, remaining deep to the platysma. The platysma is typically absent along the posterior border of the sternocleidomastoid, placing the nerve at greatest risk for injury in this location.

Facial Spaces

The triangular midcheek, following loss of youthful convexities, separates into three distinct surface segments (i.e., lid-cheek, malar, and

nasolabial) separated by grooves (i.e., palpebro-malar groove, nasojugal groove, and midcheek groove) (Fig. 3).⁴

Spaces separate superficial and deeper facial layers, and serve as glide planes over which superficial soft tissues move to generate facial expression.⁴ The laxity that accompanies facial aging causes superficial tissues to sag over the broad facial spaces (i.e., preseptal space, prezygomatic space, premasseteric space, masticator space, and oral cavity), yet remain attached by stout retaining ligaments (i.e., orbitomalar, zygomatic, and upper masseteric ligaments) at the perimeter of spaces.⁴

The spaces are relatively bloodless, safe dissection planes, given that nerves and vessels pass within and deep to the ligaments that outline their perimeters (i.e., transverse facial artery perforator through the zygomatic ligament and zygomatic branch of the facial nerve near the zygomatic and upper masseteric ligaments) (Fig. 4).²⁴

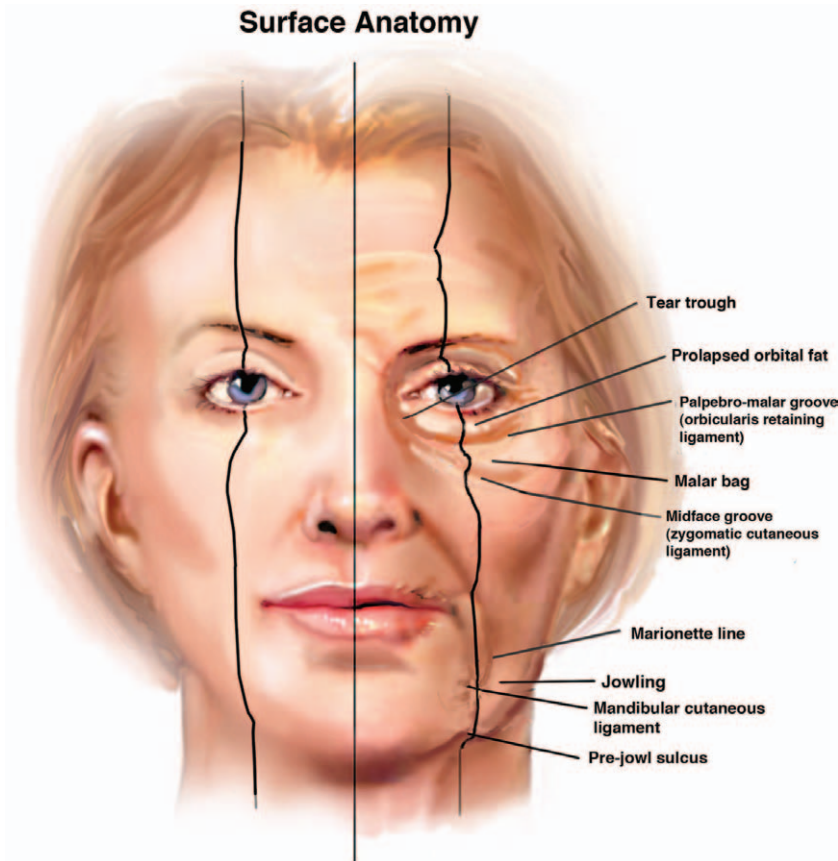


Fig. 3. Surface anatomy of facial aging. The tear trough/nasojugal groove, palpebro-malar groove, and midcheek groove occur secondary to underlying periorbital and cheek retaining ligament attachments to overlying skin. (From Alghoul M, Codner MA. Retaining ligaments of the face: Review of anatomy and clinical applications. *Aesthet Surg J.* 2013;33:769–782, © 2013 by The American Society for Aesthetic Plastic Surgery, Inc. Reprinted by permission of SAGE Publications.)

Downloaded from http://journals.lww.com/plasreconsurg by RZUSYSRlyqZg+J5ivYfoV6s8t/G+hVOYyITyC2t5u b2ZMw44Nk6awDKbJm0/CBSwIBTZol4I4GjGjZnd6kQqeaPqdTYzTrn66446mqQHYZE8w20wLayDv4K55f5jimy9b230= on 1/10/2023

Relationship of Facial Nerve Branches to Retaining Ligaments of Face

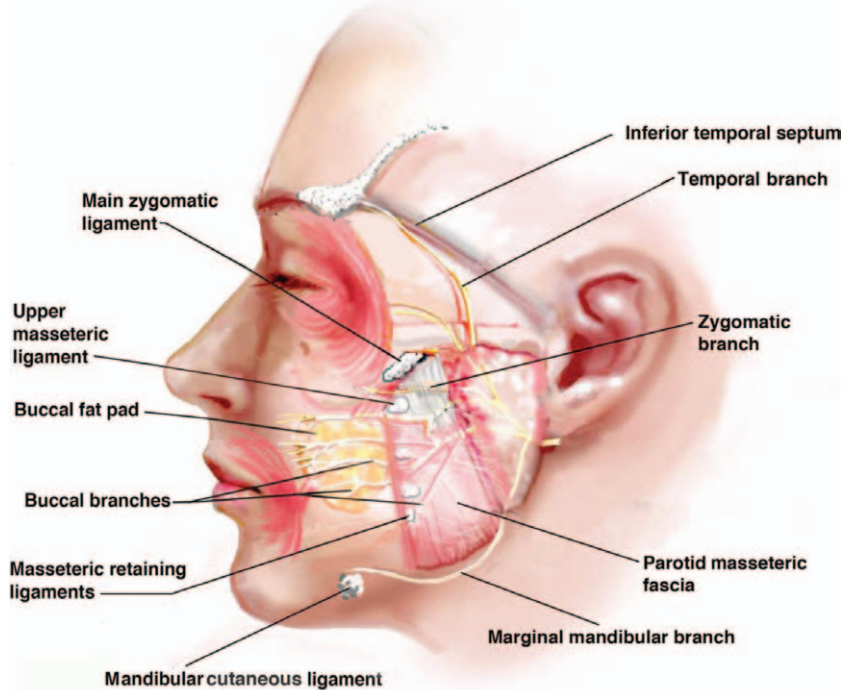


Fig. 4. Relationship of facial nerve branches to the temporal, periorbital, cheek, and mandibular retaining ligaments. Note the passage of the zygomatic branch of the facial nerve inferior to the main zygomatic ligament through which a perforator from the transverse facial artery often passes (not shown). (From Alghoul M, Codner MA. Retaining ligaments of the face: Review of anatomy and clinical applications. *Aesthet Surg J.* 2013;33:769–782, © 2013 by The American Society for Aesthetic Plastic Surgery, Inc. Reprinted by permission of SAGE Publications.)

Retaining Ligaments

The confusing nomenclature assigned to facial ligament classification systems (i.e., septae, cylinders, patches, adhesions, and direct or indirect dermal attachments), along with eponymous references, have been abandoned in the senior author's practice in favor of more anatomically relevant terms to guide surgical dissection. These include temporal, periorbital, cheek, and mandibular retaining ligaments of the face.²⁵

The need for facial ligament division during facial rejuvenation surgery has been debated. Mendelson has stated that “a prerequisite for effective lifting or repositioning of the superficial composite tissue is adequacy of surgical release of the retaining ligaments—the restraining effects of the ligaments would limit the benefits of tissue lifting to only within the boundaries of that particular space.”²⁶ Whether ligaments retain their youthful stout dimensions, or lengthen throughout the aging process, is unclear.^{27,28} The impact of

their release on the repositioning of aging facial tissues, however, should be considered.

Subcutaneous extensions of ligaments into the dermis result in dimpling, particularly in the location of the mandibular ligament, and can result in postoperative patient dissatisfaction if not adequately released.²⁵ It is unnecessary to divide the mandibular ligament in the sub-SMAS plane to generate improved jowl contours.

Adequate sub-SMAS release of the cheek retaining ligaments affords maximal movement of ptotic tissues distal to the point of release, creating a smooth, pleasing contour following SMAS flap redraping (Fig. 5).²⁵ Overzealous attempts at midface plication, without ligamentous release, can result in excessive SMAS tension and resultant abnormal grooves, and midfacial and neck bulges. An adequately dissected and/or repositioned SMAS flap will demonstrate youthful contours of the midface, jowl, and neck before skin flap redraping. Skin flaps rarely conceal the abnormalities that result from an inadequately mobilized and/or positioned SMAS layer.

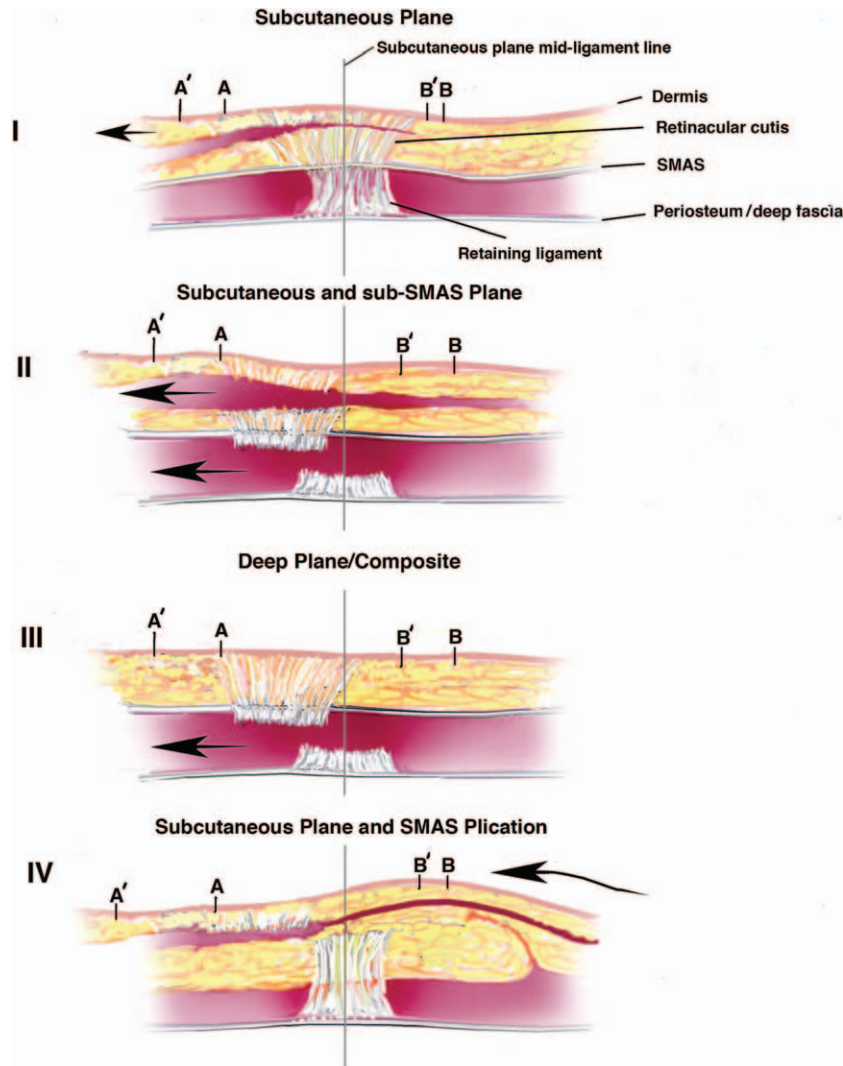


Fig. 5. Diagrammatic representation of how soft-tissue release affects repositioning of tissues distal to the point of release. *A* is the point where the dissection starts, and *B* is the tissue (i.e., jowls) intended to be repositioned. *A'* and *B'*, respectively, represent the repositioning of *A* and *B* after soft-tissue anchoring/redraping. Above, subcutaneous face lift; second row, SMAS flap; third row, deep plane and composite face lift; and below, SMAS plication. (From Alghoul M, Codner MA. Retaining ligaments of the face: Review of anatomy and clinical applications. *Aesthet Surg J.* 2013;33:769–782, © 2013 by The American Society for Aesthetic Plastic Surgery, Inc. Reprinted by permission of SAGE Publications.)

PREOPERATIVE ASSESSMENT AND PATIENT SAFETY

Gender

The incidence of postoperative hematoma after face lift is 4 to 8 percent for men and 1 to 3 percent for women. Gender therefore has a significant association with hematoma after face lift.^{29–31}

Hypertension

The association between hypertension and postoperative hematoma after face lift is well

established; therefore, preoperative blood pressure control is considered as important as intraoperative and postoperative blood pressure control for hematoma risk reduction.^{31–33}

Anticoagulants, Antiplatelet Agents, and Nonsteroidal Antiinflammatory Drugs

The association of anticoagulants, antiplatelet agents, and nonsteroidal antiinflammatory drugs with postoperative hematoma after rhytidectomy is well known; therefore, their use is discontinued for 2 weeks before surgery.^{31,32}

Ultimately, the decision to stop, bridge, or continue a medication that predisposes to perioperative bleeding, but that may be essential for cardiovascular risk reduction, should be made in conjunction with a cardiologist, internist, or hematologist.³⁴ The authors use the 2005 Caprini risk-assessment model on all patients. Use of chemoprophylaxis in patients who score a 7 or greater is considered. From our perspective, the hematoma risk associated with chemoprophylaxis use in facial rejuvenation surgery is prohibitive. Patients who exceed a score of 7 before facial rejuvenation surgery should not undergo general anesthesia, and operative time should be limited. All patients receive mechanical prophylaxis, including perioperative use of an antiembolic compression hose and sequential compression devices.

Herbal Medications and Supplements

The cosmetic patient population uses herbal medications and supplements more commonly than the general public.³⁵ Many of these medications predispose to bleeding, volume depletion, and/or postoperative sedation. A “top 10” list of herbal medications for patients to avoid perioperatively has been described, and includes chondroitin, ephedra, echinacea, glucosamine, ginkgo biloba, goldenseal, milk thistle, ginseng, kava, and garlic.³⁵

Smoking

Skin flap necrosis is 12 times more common in smokers who undergo a face lift.^{36–39} A large, recent meta-analysis demonstrated that smoking doubles to triples the odds of developing wound necrosis, dehiscence, and surgical-site infection.⁴⁰ Environmental tobacco exposure may also be a preoperative risk factor for skin necrosis after face-lift surgery, and spousal/partner smoking cessation should be suggested during preoperative assessment.⁴¹

The optimal duration of smoking cessation before surgery is 4 weeks, with each week of cessation progressively reducing operative risk.⁴² Nicotine replacement therapy can double a patient’s chances of stopping smoking, and has been shown to reduce wound healing complications to levels comparable to that of smoking cessation alone.⁴³ Medical aids to promote smoking cessation are available.⁴⁴ If a surgeon feels a smoking cessation plan was not followed, urine cotinine testing can be conducted. This quick, inexpensive assay has a sensitivity of 98 percent.⁴⁴

VARIATIONS IN TECHNIQUE

“Facelifts have more similarities than differences in their basic approach.”² Periauricular skin incisions, varying degrees of undermining, SMAS manipulation, and skin redraping comprise the standard description of most face-lifting techniques. Century-old publications describe the principles of skin-only face lifts. Techniques subsequently evolved after Skoog’s description of a dense connective tissue layer deep to the skin surface in 1974, identified as the SMAS by Mitz and Peyronie.⁴⁵ SMAS manipulation allowed for more durable results, tension diversion away from skin closure, and superficial fat repositioning. The senior author has found that the high-SMAS lift offers the most durable, most pleasing jawline and cervicomental angle possible, making this his preferred technique. The following descriptions offer perspective of the established pros and cons of the widely recognized face-lifting techniques.

Subcutaneous Face Lift

Subcutaneous lifting heralds from century-old techniques. The lift may vary from a skin pinch to wide undermining that permits flap elevation and repositioning in a single vector. Although it can be performed rapidly, with a respectable safety profile, its longevity is limited by normal skin physiology—stress relaxation and creep. Most abnormal sequelae of face lifting (i.e., tragal distortion, hairline displacement, pixie ear deformity, and lateral facial sweep) can be correlated with relying on skin tension during closure. A youthful face is not “tightly pulled.” Subcutaneous flap elevation is one component of our approach to face lifting (Fig. 6). (**See Video, Supplemental Digital Content 1**, which demonstrates skin flap elevation from the fixed/mobile SMAS along with its postauricular dissection. This video is available in the “Related Videos” section of the full-text article on PRSJournals.com or at <http://links.lww.com/PRS/B908>.)

Subcutaneous Face Lift with SMAS Manipulation

Mobile SMAS manipulation created understanding that facial shape could be changed by suturing, (re)suspending, and supporting deep soft tissues. The S-lift described by Fulton et al. and the minimal access cranial suspension described by Tonnard et al. rely on purse-string suture lifting of the neck, jowl, and/or midface.^{46–48} A plethora of SMAS plication techniques exist, generally differing in the vectors applied to the mobile SMAS (Fig. 7). Advocates suggest reduced

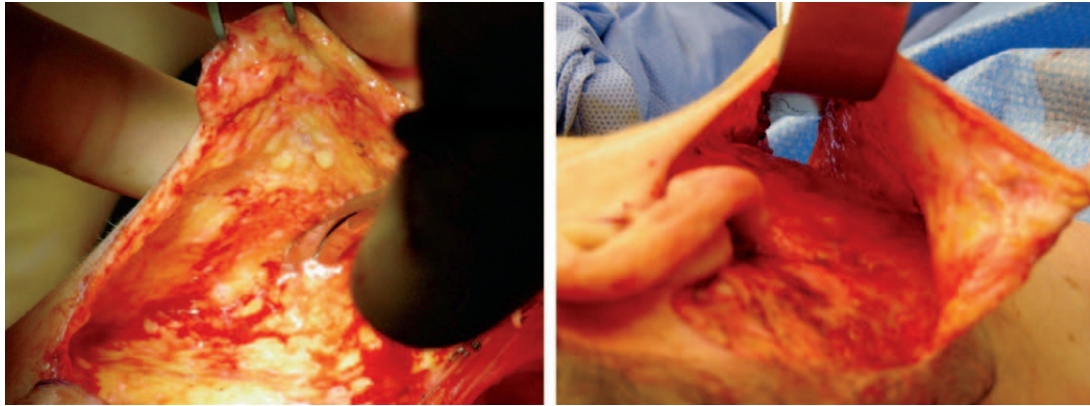
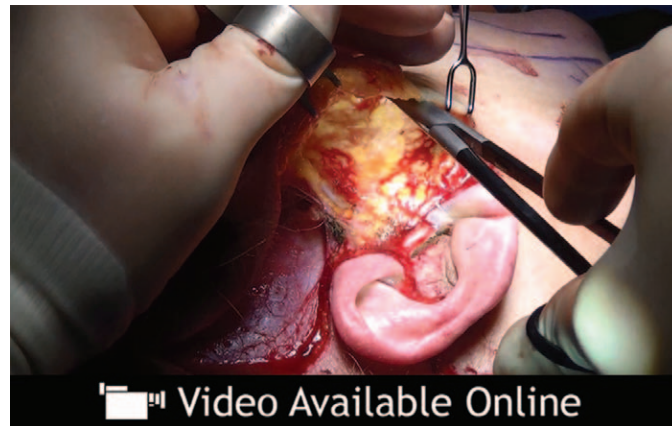

Fig. 6. The initial incision passes from the temporal hairline, along the helical root, into a retrotragal position, anteriorly at a 90-degree angle from the incisura, and around the lobule. A regular length scar is used, as the neck is frequently addressed with retroauricular SMAS transposition and platysmal plication. (*Left*) Careful scissor dissection is performed to ensure adequacy of skin flap thickness. (*Right*) Extent of subcutaneous flap undermining is shown. The tip of the retractor end rests within the submental crease incision.



Video 1. Supplemental Digital Content 1 demonstrates skin flap elevation from the fixed/mobile SMAS along with its postauricular dissection. This video is available in the “Related Videos” section of the full-text article on PRSJournal.com or at <http://links.lww.com/PRS/B908>.

complication rates and recovery times compared to more aggressive SMAS flap procedures.⁴⁹ Nerve ligature with resultant neurapraxia, cheese-wiring of suture through tissues, traction dimpling, and longevity of support are possible.

Lateral SMASectomy

The removal of a strip of SMAS, 2 to 4 cm in width, parallel to the nasolabial fold, along a trajectory toward the lateral canthus and overlying the anterior portion of the parotid gland, has proved advantageous in our hands for facial thinning in patients with “heavy” faces. As Baker described, the strip is excised immediately superficial to the deep facial fascia (in the same plane

as a SMAS flap).⁵⁰ Advocates cite advantages over simple SMAS plication, including cheek ligament (masseteric and zygomatic) release during the SMAS strip excision. Plication pulls on unreleased facial ligaments. Facial nerve branches are at risk when dissection extends anterior to the anterior border of the parotid, and midfacial/malar pad lifting may be difficult to achieve or sustain.

SMAS Flap: Extended and High

Dual-plane approaches, incorporating both a subcutaneous and a SMAS flap, have proved effective for neck, jowl, and midface lifting (Figs. 8 and 9).^{28,51} Differential tension between the two flaps avoids reliance on skin tension

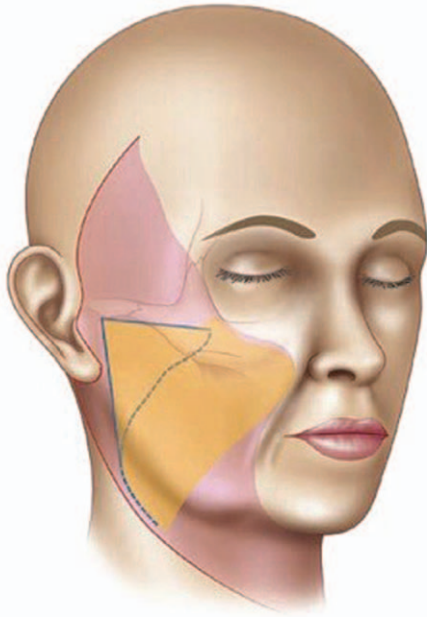

Fig. 7. Ninety-degree SMAS plication. The junction between the zygoma and zygomatic arch is palpated, and methylene blue is used to mark a horizontal limb from this junction to the external auditory meatus along the lower border of the arch. The vertical limb is carried inferiorly, and then along the posterior border of the platysma. The mobile SMAS is grasped and pulled posteriorly to the extent that it will oppose the horizontal and vertical limbs before suture anchoring.

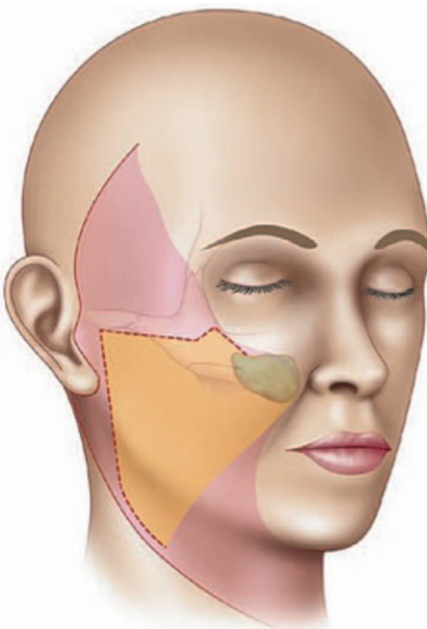


Fig. 8. Diagrammatic representation of the extended-SMAS methylene blue markings. From the junction of the zygoma and zygomatic arch, the horizontal limb is carried toward the lateral canthus and then inferiorly toward the alar rim.

for shaping, hairline displacement, and the lateral sweep and wrinkle abnormalities of skin flaps set in a vertical direction. The SMAS flap is inset in a superolateral vector, and the skin flap is inset in a lateral vector. The SMAS flap becomes more fragile as dissection is carried anteriorly. Facial nerve branches are at risk, but can be easily avoided with the assistance of tumescent infiltration placed at the start of the case (Fig. 10) (**See Video, Supplemental Digital Content 2**, which demonstrates marking and elevation of the high-SMAS flap atop the parotid-masseteric fascia, with preservation of facial nerve branches. This video is available in the “Related Videos” section of the full-text article on PRSJJournal.com or at <http://links.lww.com/PRS/B909>.)

The extended and high-SMAS flaps are designed to rejuvenate the midface through malar fat pad elevation after detachment of the malar fat pad from upper lip elevators. Infra-orbital fill and lower eyelid support are benefits, and can be particularly advantageous when used as an adjuvant approach for treating lower lid retraction. Although fat grafting is commonly used for malar region augmentation in conjunction with one’s chosen technique, we have not regularly incorporated its use in practice. The high-SMAS technique’s mobilization of malar fat, and relocation to its proper anatomical location, has met our and our patient’s expectations of midface rejuvenation. Supplementary fill with volumizing filler, if necessary, can be used. When doing so, we use aesthetic judgment to optimize fill contours, rather than deliberately focusing on fill of one facial compartment relative to another. The high-SMAS technique also offers the advantage of firm SMAS flap fixation to the deep temporal fascia superior to the zygomatic arch, and can be supplemented with a SMAS transposition flap for neck contouring (Fig. 11). (**See Video, Supplemental Digital Content 3**, which demonstrates SMAS-platysma flap inseting to establish facial contours before skin redraping. This video is available in the “Related Videos” section of the full-text article on PRSJJournal.com or at <http://links.lww.com/PRS/B910>.)

Deep Plane, Composite, and Subperiosteal Face Lifting

Deep plane lifting of the skin, subcutaneous tissue, and SMAS as a single flap was established by Tord Skoog in 1974.²⁷ His work, and Owsley’s

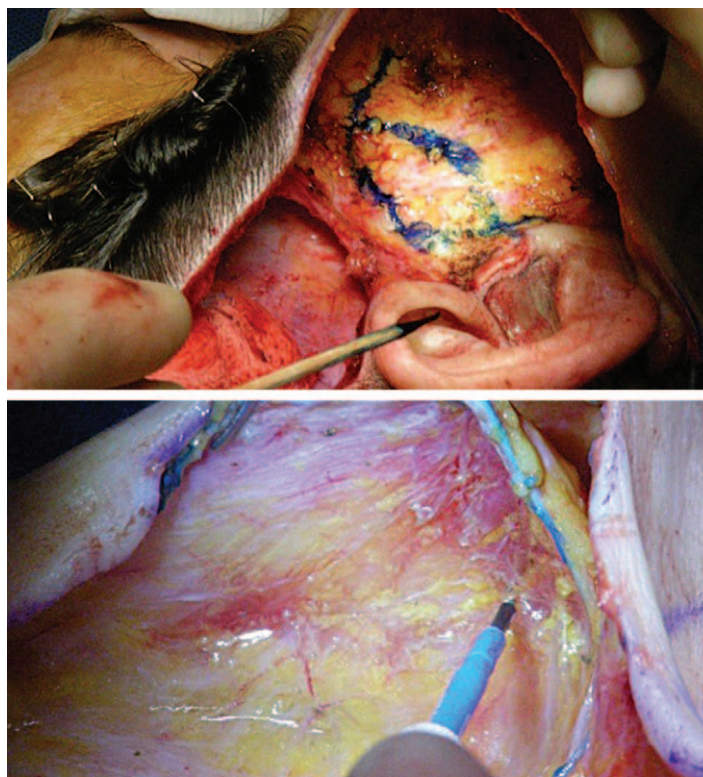


Fig. 9. (Above) The high-SMAS marking is carried posteriorly from the apex of the horizontal limb triangle, passing above the arch, and toward the vertical methylene blue limb. (Below) The SMAS flap is elevated just deep to the sparse sub-SMAS fatty layer.

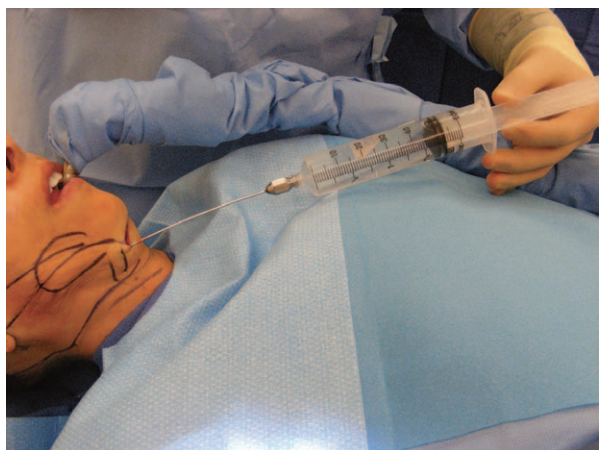


Fig. 10. Tumescent infiltration is placed through small preauricular/postauricular and submental stab incisions. One hundred milliliters is placed in each facial hemisphere, and 50 ml is placed in the neck.

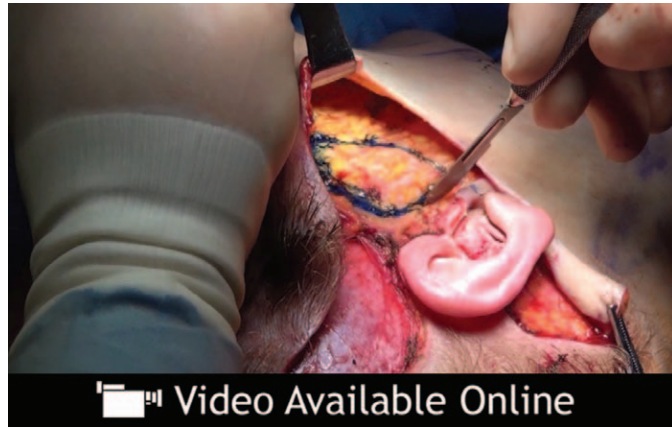in 1977,⁵² opened the door to multiple variations of SMAS manipulation. The lifting of all tissue layers as a single unit, however, limits movement to a unidirectional plane. Concerns for facial nerve injury are comparable to all techniques that

incorporate sub-SMAS dissection. Hamra's composite lift combines lifting of the orbicularis oculi, malar fat, and platysma unit.⁵³ The technique affords midfacial rejuvenation through superomedial orbicularis-malar fat repositioning, which is not offered by the deep plane technique alone.⁵⁴ Subperiosteal approaches are enhanced through the use of endoscopic instrumentation. The technique offers avoidance of facial nerve branches, but offers little improvement in neck contour and has little to no effect on facial skin.

Final Note on Technique Selection

Facial structure and framework should be established before redraping the skin flap. The skin flap should simply lie across the foundation that the SMAS lift and ancillary procedures have established. Closing the skin under tension leads to unnatural and untoward outcomes. Excellent results can be achieved with the high-SMAS technique (Fig. 12). We offer the following as a summary of patient assessment and technique selection. In the primary thin-faced patient, the high-SMAS technique is used for its added benefit of malar augmentation. Patients with heavy jowls,

Downloaded from http://journals.lww.com/plasreconsurg by RZUSYSRlyqZg+J5ivYjoVv6s8t/G+hNOVYjTYC2t5u
bZ2Mw+4Nk6awDKbkfm0/CBSWB/TZvol.4I4IgjZnd6kOqeaPqdTYzTrn66+46mqdQHYZE8w20wL AyDV4K55fijmy9b230= on
1/10/2023



Video 2. Supplemental Digital Content 2 demonstrates marking and elevation of the high-SMAS flap atop the parotid-masseteric fascia, with preservation of facial nerve branches. This video is available in the “Related Videos” section of the full-text article on PRSJournals.com or at <http://links.lww.com/PRS/B909>.

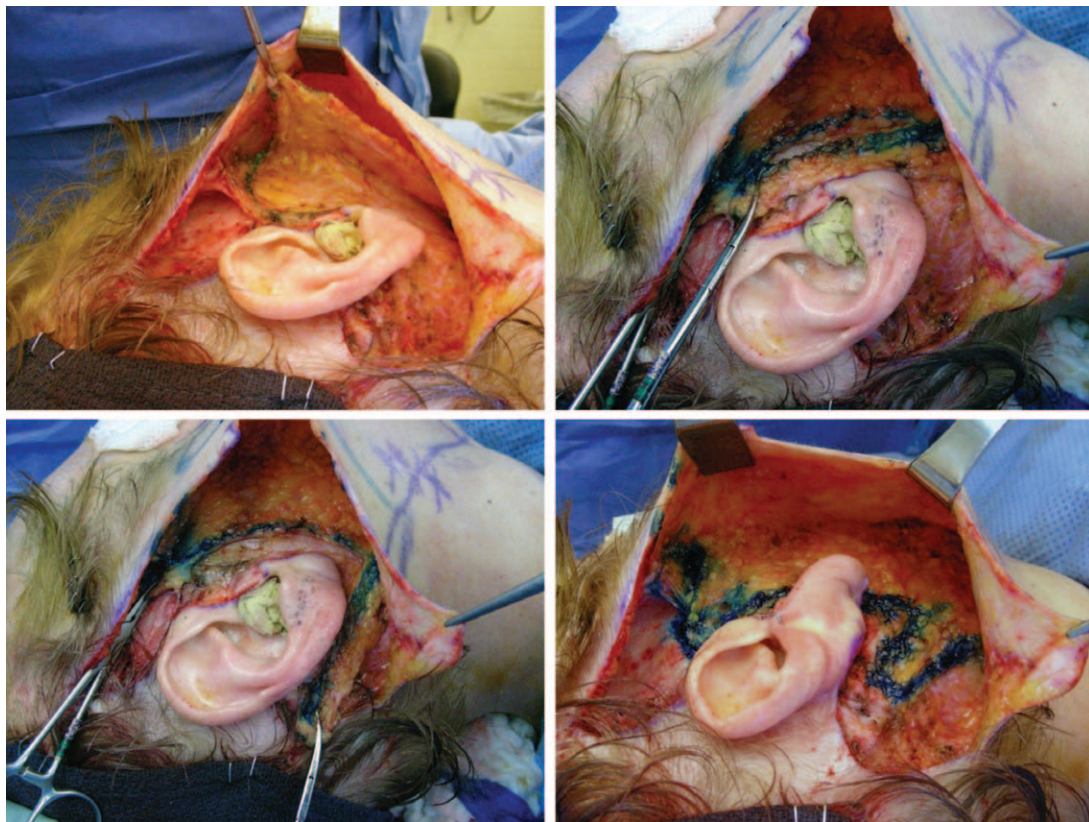
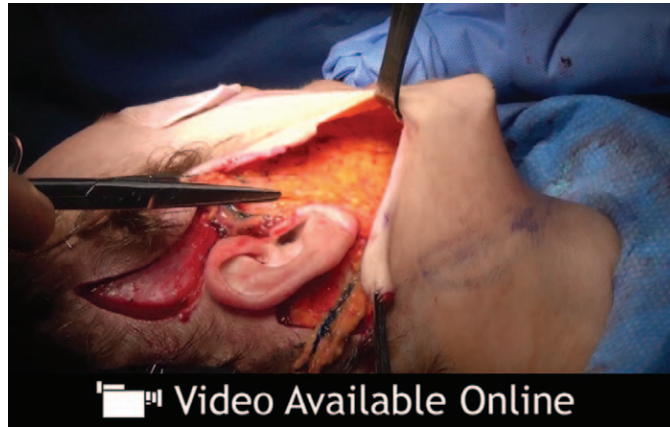

Fig. 11. (Above, left) Extent of high-SMAS flap elevation. (Above, right) High-SMAS flap after postauricular flap division, and before inset and postauricular flap transposition. (Below, left) Postauricular SMAS flap transposition for supplemental neck contouring. (Below, right) High-SMAS flap after complete inset.

and round faces, undergo a lateral SMASectomy. This technique offers the dual benefit of facial thinning and locating the vector of SMAS pull closer to

the heavy jowl to elicit change. Secondary/tertiary face-lift patients undergo a 90-degree SMAS-plication along the arch and preauricular regions.



Video 3. Supplemental Digital Content 3 demonstrates SMAS-platysma flap inseting to establish facial contours before skin redraping. This video is available in the “Related Videos” section of the full-text article on PRSJournal.com or at <http://links.lww.com/PRS/B910>.

COMPLICATIONS: EMPHASIZING PREVENTION

Hematoma

Hematoma is the most common serious complication following face lift.^{31,37,55} A 2014 meta-analysis based on 41 studies identified a 1.4 percent incidence of expanding hematoma after face lift.³⁷ Most hematomas occur in the first 12 to 24 hours after surgery.^{27,56} General anesthetic use does not appear to be a predictive risk factor.⁵⁷ No evidence exists to demonstrate that hematoma rates differ among common face-lifting techniques.

Blood Pressure Control

Maricevich et al. identified target blood pressure goals to guide perioperative care.⁵⁸ Preoperative systolic blood pressure greater than 160 mmHg and intraoperative peak pressures greater than 165 mmHg were predictive factors for hematoma. Initiation of a perioperative blood pressure control regimen has been shown to significantly reduce the incidence of postoperative hematoma after face lifts.²⁹

Clonidine is a centrally acting alpha-agonist antihypertensive also used in the treatment of attention deficit hyperactivity disorder. We routinely use one dose of clonidine 0.1 mg in the recovery unit, followed by twice-a-day dosing to keep systolic blood pressure less than 140 mmHg. Anecdotally, we have noted reduction in postoperative analgesic requirements and nausea/vomiting, along with notable anxiolysis.

Ancillary Techniques That May Minimize Risk: Fibrin Glue, Quilting Sutures, and Tumescant Infiltration

A meta-analysis, including three randomized controlled trials, demonstrated that fibrin glue does not consistently reduce hematoma rates.⁵⁹ Neto and colleagues reduced their incidence of hematoma from 12 percent, in patients that received epinephrine-containing infiltration, to 0 percent in patients receiving quilting sutures alone after undergoing cervicofacial rhytidectomy.⁶⁰ The intraoperative attributes of tumescant infiltration, before rhytidectomy, include easier dissection of surgical planes in relatively bloodless fields, along with a reduction in postoperative edema and ecchymosis.^{61–64} Comparative study has not shown that hematoma rates differ with or without the use of tumescant infiltration.⁶⁴

Treatment

An emergent return trip to the operating room is frequently required for expanding hematomas. Untreated hematomas result in flap edema, ecchymosis, and flap necrosis. Bedside treatment with appropriate analgesic and anxiolytic control, and antisepsis, can be considered in cases of smaller, unilateral, early postoperative hematomas, before the formation of a firm coagulum.⁶⁵

Venous Thromboembolism

The American Society of Plastic Surgeons has established venous thromboembolism risk reduction guidelines based on the 2005 Caprini risk stratification tool.⁶⁶ Contrary to the findings

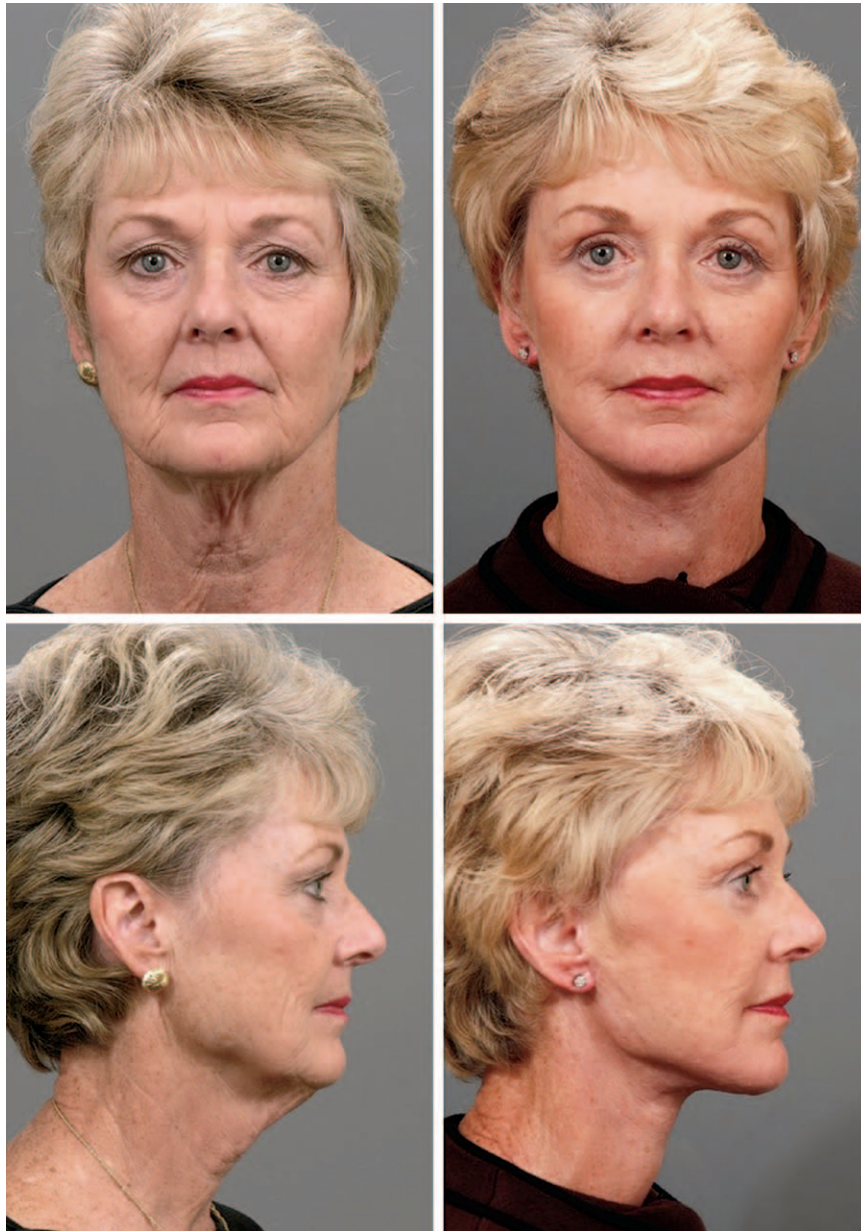

Fig. 12. Preoperative and postoperative results from the frontal (*above*) and lateral (*below*) views using the high-SMAS technique.

of the Venous Thromboembolism Prevention Study, Durnig and Jungwirth demonstrated a significantly increased risk of hematoma after rhytidectomy in patients that received chemoprophylaxis.⁶⁷ Treated patients had a 16.1 percent incidence of hematoma, compared with the 1.1 percent incidence in controls. Symptomatic venous thromboembolism rates did not differ.

Facial Nerve Injury

Injury to the facial nerve occurs in 0.5 to 2.6 percent of face lifts.²¹ Although the buccal branch

has been previously cited as the most commonly injured nerve branch, cross-innervation with the zygomatic branch makes clinical sequelae unlikely.²⁷

Temporal and marginal branch injuries result in patient anxiety and abnormal facial presentation. If brow ptosis and/or lip/oral commissural elevation persists for more than 6 weeks, one may consider surgical intervention. Botulinum toxin can be used to temporize brow/oral symmetry during the waiting period. Brow lifting and/or division of the functional deep angularis oris muscle are definitive surgical treatment options.

Cervical branch injury is often inconsequential; however, in patients in whom the cervical branch innervates both the platysma and deep angularis oris in continuity, “pseudo-paralysis” of the marginal mandibular nerve may result.^{21,68,69} In this circumstance, the platysma acts as a lip depressor, but intact lip eversion (from intact mentalis function) indicates that the marginal mandibular nerve is functional.

Great Auricular Nerve Injury

Injury to the great auricular nerve may occur in up to 6 to 7 percent of face lifts, with resultant lobular numbness.⁷⁰ If injury is identified at the time of the procedure, epineurial repair is recommended. Surgical decompression can be considered in cases of neurapraxia that persists after rhytidectomy.⁷¹

Facial Edema and Ecchymosis

A Cochrane review from 2014 indicates that there is no clear benefit to corticosteroid use for reduction in facial edema and ecchymosis following facial plastic surgery.⁷² A study using lymphoscintigraphy after one of three face-lift techniques (i.e., subcutaneous, SMASectomy, or high-SMAS composite) demonstrated no differences in lymphatic drainage patterns, with complete return to baseline drainage patterns at 6 months postoperatively.⁷³

Arnica montana

Arnica montana contains the anti-inflammatory compound helenalin. Prospective randomized trials are inconclusive with respect to the benefit

the herb has on ecchymosis and edema reduction after face lift.^{74–76}

Bromelain

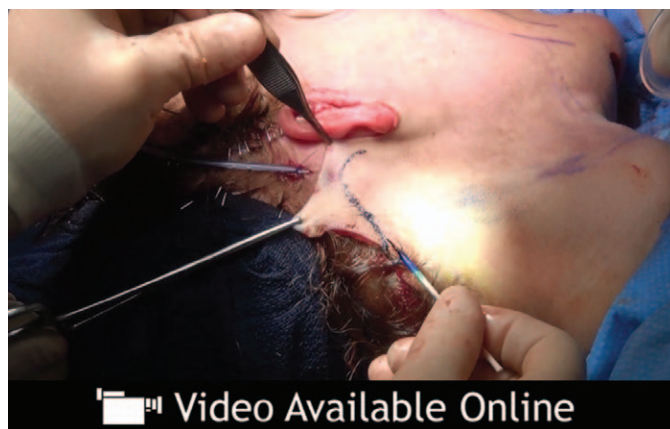Bromelain, a mixture of enzymes derived from the core and juice of pineapples, is an herbal supplement used to reduce postoperative edema and ecchymosis. Its use following rhytidectomy has not been evaluated.⁷⁷ Its efficacy in reducing postoperative edema reduction has been confirmed in a prospective, randomized, double-blind, placebo-controlled trial following orthognathic surgery.⁷⁸


Pixie-Ear Deformity

Pixie ear results from excessive tension placed on the lobule during skin flap inset.^{79–83} The best technique for treatment is prevention. (See **Video, Supplemental Digital Content 4**, which demonstrates a technique for skin flap inset that consistently results in minimal skin tension and avoidance of the pixie-ear deformity. This video is available in the “Related Videos” section of the full-text article on PRSJJournal.com or at <http://links.lww.com/PRS/B911>.)

Skin Flap Necrosis

Excessive subcutaneous thinning and tension on inset can predispose to skin necrosis and slough. This most commonly occurs in the postauricular location. To help avert this problem, the initial postauricular incision is carried down to the level of the sternocleidomastoid fascia before inferior undermining. Evidence clearly associates smoking with an increased risk of skin flap necrosis.^{38,39,84,85}



 Video Available Online

Video 4. Supplemental Digital Content 4 demonstrates a technique for skin flap inset that consistently results in minimal skin tension and avoidance of the pixie-ear deformity. This video is available in the “Related Videos” section of the full-text article on PRSJJournal.com or at <http://links.lww.com/PRS/B911>.

The transverse facial artery perforator, as opposed to the SMAS flap, may be responsible for the majority of lateral skin flap perfusion.⁸⁶ When ligated, a reduction in preauricular skin perfusion is noted.⁸⁷

Parotid Fistulae

Exposed/divided parotid tissue should be cauterized to seal off ductules, followed by closure of the SMAS atop the defect. Aspiration, scopolamine patches, and botulinum toxin have been used with success for smaller, established pseudocysts. Closed suction drainage may be needed for larger pseudocysts.⁸⁸⁻⁹⁰

OUTCOMES: EMPHASIZING THE PATIENT'S PERSPECTIVE

Several authors have presented face-lifting outcomes assessments.⁹¹⁻⁹⁶ The only available systematic review on the topic was published in 2011.⁹⁶ No differences in surgeon- or researcher-perceived outcome or complication rates were identified among the various techniques reviewed. A valid, reliable tool for the evaluation of patient satisfaction was not used. Future discussions should focus on the technique that reliably and consistently produces high scores in one's hands while using the most useful and valid tool currently available to assess patient perception of outcome after face lifting, the FACE-Q.⁹⁷⁻¹⁰³

Mark A. Codner, M.D.

Mark Codner M.D. Plastic Surgery
1800 Howell Mill Road, Suite 140
Atlanta, Ga. 30318
macodner@gmail.com

PATIENT CONSENT

Dr. Codner reports that he has written consent for use of the patients' images.

REFERENCES

1. American Society of Plastic Surgeons. 2013 cosmetic plastic surgery statistics. Available at: <http://asps.org/stats.htm>. Accessed October 9, 2014.
2. Lambros V. Models of facial aging and implications for treatment. *Clin Plast Surg*. 2008;35:319-327; discussion 317.
3. Mendelson BC, Muzaffar AR, Adams WP Jr. Surgical anatomy of the midcheek and malar mounds. *Plast Reconstr Surg*. 2002;110:885-896; discussion 897.
4. Mendelson BC, Jacobson SR. Surgical anatomy of the midcheek: Facial layers, spaces, and the midcheek segments. *Clin Plast Surg*. 2008;35:395-404; discussion 393.
5. Mendelson BC, Hartley W, Scott M, McNab A, Granzow JW. Age-related changes of the orbit and midcheek and

- the implications for facial rejuvenation. *Aesthetic Plast Surg*. 2007;31:419-423.
6. Rohrich RJ, Pessa JE. The fat compartments of the face: Anatomy and clinical implications for cosmetic surgery. *Plast Reconstr Surg*. 2007;119:2219-2227; discussion 2228.
7. Coleman SR. Facial recontouring with lipostructure. *Clin Plast Surg*. 1997;24:347-367.
8. Jansen DA, Graivier MH. Evaluation of a calcium hydroxylapatite-based implant (Radiesse) for facial soft-tissue augmentation. *Plast Reconstr Surg*. 2006;118(Suppl):22S-30S, discussion 31S.
9. Philipp-Dormston WG, Eccleston D, De Bouille K, Hilton S, van den Elzen H, Nathan M. A prospective, observational study of the volumizing effect of open-label aesthetic use of Juvéderm VOLUMA with lidocaine in mid-face area. *J Cosmet Laser Ther*. 2014;16:171-179.
10. Matarasso A. Managing the components of the aging neck: From liposuction to submentalplasty, to neck lift. *Clin Plast Surg*. 2014;41:85-98.
11. Innocenti A, Andretto Amodeo C, Ciancio F. Wide-undermining neck liposuction: Tips and tricks for good results. *Aesthetic Plast Surg*. 2014;38:662-669.
12. Pitanguy I, Ramos AS. The frontal branch of the facial nerve: The importance of its variations in face lifting. *Plast Reconstr Surg*. 1966;38:352-356.
13. Dingman RO, Grabb WC. Surgical anatomy of the mandibular ramus of the facial nerve based on the dissection of 100 facial halves. *Plast Reconstr Surg Transplant Bull*. 1962;29:266-272.
14. Nelson DW, Gingrass RP. Anatomy of the mandibular branches of the facial nerve. *Plast Reconstr Surg*. 1979;64:479-482.
15. Zani R, Fadul R Jr, Da Rocha MA, Santos RA, Alves MC, Ferreira LM. Facial nerve in rhytidoplasty: Anatomic study of its trajectory in the overlying skin and the most common sites of injury. *Ann Plast Surg*. 2003;51:236-242.
16. Agarwal CA, Mendenhall SD III, Foreman KB, Owsley JQ. The course of the frontal branch of the facial nerve in relation to fascial planes: An anatomic study. *Plast Reconstr Surg*. 2010;125:532-537.
17. Stuzin JM, Wagstrom L, Kawamoto HK, Wolfe SA. Anatomy of the frontal branch of the facial nerve: The significance of the temporal fat pad. *Plast Reconstr Surg*. 1989;83:265-271.
18. Gosain AK, Sewall SR, Yousif NJ. The temporal branch of the facial nerve: How reliably can we predict its path? *Plast Reconstr Surg*. 1997;99:1224-1233; discussion 1234.
19. Gosain AK. Surgical anatomy of the facial nerve. *Clin Plast Surg*. 1995;22:241-251.
20. Correia Pde C, Zani R. Surgical anatomy of the facial nerve, as related to ancillary operations in rhytidoplasty. *Plast Reconstr Surg*. 1973;52:549-552.
21. Owsley JQ, Agarwal CA. Safely navigating around the facial nerve in three dimensions. *Clin Plast Surg*. 2008;35:469-477, v.
22. Trussler AP, Stephan P, Hatef D, Schaverien M, Meade R, Barton FE. The frontal branch of the facial nerve across the zygomatic arch: Anatomical relevance of the high-SMAS technique. *Plast Reconstr Surg*. 2010;125:1221-1229.
23. Baker DC, Conley J. Avoiding facial nerve injuries in rhytidectomy: Anatomical variations and pitfalls. *Plast Reconstr Surg*. 1979;64:781-795.
24. Mendelson BC, Wong CH. Surgical anatomy of the middle premasseter space and its application in sub-SMAS face lift surgery. *Plast Reconstr Surg*. 2013;132:57-64.
25. Alghoul M, Codner MA. Retaining ligaments of the face: Review of anatomy and clinical applications. *Aesthet Surg J*. 2013;33:769-782.

26. Mendelson BC. Surgery of the superficial musculoaponeurotic system: Principles of release, vectors, and fixation. *Plast Reconstr Surg.* 2001;107:1545–1552; discussion 1553.
27. Warren RJ, Aston SJ, Mendelson BC. Face lift. *Plast Reconstr Surg.* 2011;128:747e–764e.
28. Stuzin JM, Baker TJ, Gordon HL, Baker TM. Extended SMAS dissection as an approach to midface rejuvenation. *Clin Plast Surg.* 1995;22:295–311.
29. Baker DC, Stefani WA, Chiu ES. Reducing the incidence of hematoma requiring surgical evacuation following male rhytidectomy: A 30-year review of 985 cases. *Plast Reconstr Surg.* 2005;116:1973–1985; discussion 1986.
30. Baker DC, Aston SJ, Guy CL, Rees TD. The male rhytidectomy. *Plast Reconstr Surg.* 1977;60:514–522.
31. Grover R, Jones BM, Waterhouse N. The prevention of hematoma following rhytidectomy: A review of 1078 consecutive facelifts. *Br J Plast Surg.* 2001;54:481–486.
32. Abboushi N, Yezhelyev M, Symbas J, Nahai F. Facelift complications and the risk of venous thromboembolism: A single center's experience. *Aesthet Surg J.* 2012;32:413–420.
33. Berner RE, Morain WD, Noe JM. Postoperative hypertension as an etiological factor in hematoma after rhytidectomy: Prevention with chlorpromazine. *Plast Reconstr Surg.* 1976;57:314–319.
34. Haeck PC, Swanson JA, Iverson RE, et al. Evidence-based patient safety advisory: Patient selection and procedures in ambulatory surgery. *Plast Reconstr Surg.* 2009;124:6S–27S.
35. Heller J, Gabbay JS, Ghadjar K, et al. Top-10 list of herbal and supplemental medicines used by cosmetic patients: What the plastic surgeon needs to know. *Plast Reconstr Surg.* 2006;117:436–445; discussion 446.
36. Guyuron B. An evidence-based approach to face lift. *Plast Reconstr Surg.* 2010;126:2230–2233.
37. Mustoe TA, Park E. Evidence-based medicine: Face lift. *Plast Reconstr Surg.* 2014;133:1206–1213.
38. Rees TD, Liverett DM, Guy CL. The effect of cigarette smoking on skin-flap survival in the face lift patient. *Plast Reconstr Surg.* 1984;73:911–915.
39. Riefkohl R, Wolfe JA, Cox EB, McCarty KS Jr. Association between cutaneous occlusive vascular disease, cigarette smoking, and skin slough after rhytidectomy. *Plast Reconstr Surg.* 1986;77:592–595.
40. Sørensen LT. Wound healing and infection in surgery: The clinical impact of smoking and smoking cessation. A systematic review and meta-analysis. *Arch Surg.* 2012;147:373–383.
41. Matarasso A. Environmental tobacco smoke: The risks of passive smoking in facial surgery. *Ann Plast Surg.* 1993;31:573.
42. Mills E, Eyawo O, Lockhart I, Kelly S, Wu P, Ebbert JO. Smoking cessation reduces postoperative complications: A systematic review and meta-analysis. *Am J Med.* 2011;124:144–154.e8.
43. Sorensen LT, Karlsmark T, Gottrup F. Abstinence from smoking reduces incisional wound infection: A randomized controlled trial. *Ann Surg.* 2003;238:1–5.
44. Rinker B. The evils of nicotine: An evidence-based guide to smoking and plastic surgery. *Ann Plast Surg.* 2013;70:599–605.
45. Mitz V, Peyronie M. The superficial musculo-aponeurotic system (SMAS) in the parotid and cheek area. *Plast Reconstr Surg.* 1976;58:80–88.
46. Fulton JE, Saylan Z, Helton P, Rahimi AD, Golshani M. The S-lift facelift featuring the U-suture and O-suture combined with skin resurfacing. *Dermatol Surg.* 2001;27:18–22.
47. Tonnard P, Verpaele A, Monstrey S, et al. Minimal access cranial suspension lift: A modified S-lift. *Plast Reconstr Surg.* 2002;109:2074–2086.
48. Verpaele A, Tonnard P, Gaia S, Guerao FP, Pirayesh A. The third suture in MACS-lifting: Making midface-lifting simple and safe. *J Plast Reconstr Aesthet Surg.* 2007;60:1287–1295.
49. Berry MG, Davies D. Platysma-SMAS plication facelift. *J Plast Reconstr Aesthet Surg.* 2010;63:793–800.
50. Baker DC. Lateral SMASectomy. *Plast Reconstr Surg.* 1997;100:509–513.
51. Marten TJ. High SMAS facelift: Combined single flap lifting of the jawline, cheek, and midface. *Clin Plast Surg.* 2008;35:569–603, vi.
52. Owsley JQ Jr. Platysma-fascial rhytidectomy: A preliminary report. *Plast Reconstr Surg.* 1977;60:843–850.
53. Hamra ST. Composite rhytidectomy. *Plast Reconstr Surg.* 1992;90:1–13.
54. Hamra ST. Repositioning the orbicularis oculi muscle in the composite rhytidectomy. *Plast Reconstr Surg.* 1992;90:14–22.
55. Jones BM, Grover R. Avoiding hematoma in cervicofacial rhytidectomy: A personal 8-year quest. Reviewing 910 patients. *Plast Reconstr Surg.* 2004;113:381–387; discussion 388.
56. Niamtu J III. Expanding hematoma in face-lift surgery: Literature review, case presentations, and caveats. *Dermatol Surg.* 2005;31:1134–1144; discussion 1144.
57. Rees TD, Barone CM, Valauri FA, Ginsberg GD, Nolan WB III. Hematomas requiring surgical evacuation following face lift surgery. *Plast Reconstr Surg.* 1994;93:1185–1190.
58. Maricevich MA, Adair MJ, Maricevich RL, Kashyap R, Jacobson SR. Facelift complications related to median and peak blood pressure evaluation. *Aesthetic Plast Surg.* 2014;38:641–647.
59. Por YC, Shi L, Samuel M, Song C, Yeow VK. Use of tissue sealants in face-lifts: A metaanalysis. *Aesthetic Plast Surg.* 2009;33:336–339.
60. Neto JC, Rodriguez Fernandez DE, Boles M. Reducing the incidence of hematomas in cervicofacial rhytidectomy: New external quilting sutures and other ancillary procedures. *Aesthetic Plast Surg.* 2013;37:1034–1039.
61. Brody GS. The tumescent technique for face lift. *Plast Reconstr Surg.* 1994;94:407.
62. Schoen SA, Taylor CO, Owsley TG. Tumescent technique in cervicofacial rhytidectomy. *J Oral Maxillofac Surg.* 1994;52:344–347.
63. Latrenta GS. Tumescent cervicofacial rhytidectomy. *Aesthet Surg J.* 1998;18:423–430.
64. Jones BM, Grover R. Reducing complications in cervicofacial rhytidectomy by tumescent infiltration: A comparative trial evaluating 678 consecutive face lifts. *Plast Reconstr Surg.* 2004;113:398–403.
65. Baker DC, Chiu ES. Bedside treatment of early acute rhytidectomy hematomas. *Plast Reconstr Surg.* 2005;115:2119–2222; discussion 2123.
66. Murphy RX Jr, Alderman A, Gutowski K, et al. Evidence-based practices for thromboembolism prevention: Summary of the ASPS Venous Thromboembolism Task Force Report. *Plast Reconstr Surg.* 2012;130:168e–175e.
67. Durnig P, Jungwirth W. Low-molecular-weight heparin and postoperative bleeding in rhytidectomy. *Plast Reconstr Surg.* 2006;118:502–507; discussion 508.
68. Ellenbogen R. Pseudo-paralysis of the mandibular branch of the facial nerve after platysmal face-lift operation. *Plast Reconstr Surg.* 1979;63:364–368.
69. Daane SP, Owsley JQ. Incidence of cervical branch injury with “marginal mandibular nerve pseudo-paralysis” in patients undergoing face lift. *Plast Reconstr Surg.* 2003;111:2414–2418.
70. Lefkowitz T, Hazani R, Chowdhry S, Elston J, Yaremchuk MJ, Wilhelmi BJ. Anatomical landmarks to avoid injury to

- the great auricular nerve during rhytidectomy. *Aesthet Surg J*. 2013;33:19–23.
71. Barbour JR, Iorio ML, Halpern DE. Surgical decompression of the great auricular nerve: A therapeutic option for neurapraxia following rhytidectomy. *Plast Reconstr Surg*. 2014;133:255–260.
 72. da Silva EM, Hochman B, Ferreira LM. Perioperative corticosteroids for preventing complications following facial plastic surgery. *Cochrane Database Syst Rev*. 2014;6:CD009697.
 73. Meade RA, Teotia SS, Griffith LK, Barton FE. Facelift and patterns of lymphatic drainage. *Aesthet Surg J*. 2012;32:39–45.
 74. Totonchi A, Guyuron B. A randomized, controlled comparison between arnica and steroids in the management of postrhinoplasty ecchymosis and edema. *Plast Reconstr Surg*. 2007;120:271–274.
 75. Seeley BM, Denton AB, Ahn MS, Maas CS. Effect of homeopathic *Arnica montana* on bruising in face-lifts: Results of a randomized, double-blind, placebo-controlled clinical trial. *Arch Facial Plast Surg*. 2006;8:54–59.
 76. Kotlus BS, Heringer DM, Dryden RM. Evaluation of homeopathic *Arnica montana* for ecchymosis after upper blepharoplasty: A placebo-controlled, randomized, double-blind study. *Ophthalm Plast Reconstr Surg*. 2010;26:395–397.
 77. Rowe DJ, Baker AC. Perioperative risks and benefits of herbal supplements in aesthetic surgery. *Aesthet Surg J*. 2009;29:150–157.
 78. Shetty V, Mohan A. A prospective, randomized, double-blind, placebo-controlled clinical trial comparing the efficacy of systemic enzyme therapy for edema control in orthognathic surgery using ultrasound scan to measure facial swelling. *J Oral Maxillofac Surg*. 2013;71:1261–1267.
 79. Mowlavi A, Meldrum DG, Wilhelmi BJ, Russell RC, Zook EG. The “pixie” ear deformity following face lift surgery revisited. *Plast Reconstr Surg*. 2005;115:1165–1171.
 80. Mowlavi A, Zakhireh M. Avoiding the “pixie-ear” deformity following face lift surgery by differential inseting and secondary intention healing. *Aesthet Surg J*. 2005;25:467–470.
 81. Laurence VG, Wirth GA, Michaud JP, Wood DL. Surgical correction of pixie-ear defect without an exposed incision on the lobe. *Ann Plast Surg*. 2012;68:360–361.
 82. Tepper OM, Zide BM. The “YouTube” method of correcting pixie ear and poor alar base inset. *J Craniofac Surg*. 2012;23:1137–1139.
 83. Sapountzis S, Kiranantawat K, Foroglou P, et al. Correction of severe “pixie ear” deformity after rhytidectomy with modified minimal access cranial suspension lift. *Arch Plast Surg*. 2013;40:797–799.
 84. Craig S, Rees TD. The effects of smoking on experimental skin flaps in hamsters. *Plast Reconstr Surg*. 1985;75:842–846.
 85. Krueger JK, Rohrich RJ. Clearing the smoke: The scientific rationale for tobacco abstinence with plastic surgery. *Plast Reconstr Surg*. 2001;108:1063–1073; discussion 1074.
 86. Whetzel TP, Stevenson TR. The contribution of the SMAS to the blood supply in the lateral face lift flap. *Plast Reconstr Surg*. 1997;100:1011–1018.
 87. Schaverien MV, Pessa JE, Saint-Cyr M, Rohrich RJ. The arterial and venous anatomies of the lateral face lift flap and the SMAS. *Plast Reconstr Surg*. 2009;123:1581–1587.
 88. Lawson GA III, Kreymerman P, Kreyerman P, Nahai F. An unusual complication following rhytidectomy: Iatrogenic parotid injury resulting in parotid fistula/sialocele. *Aesthet Surg J*. 2012;32:814–821.
 89. Dessy LA, Mazzocchi M, Monarca C, Onesti MG, Scuderi N. Combined transdermal scopolamine and botulinum toxin A to treat a parotid fistula after a face-lift in a patient with silenomas. *Int J Oral Maxillofac Surg*. 2007;36:949–952.
 90. Lapid O, Kreiger Y, Sagi A. Transdermal scopolamine use for post-rhytidectomy sialocele. *Aesthetic Plast Surg*. 2004;28:24–28.
 91. Liu TS, Owsley JQ. Long-term results of face lift surgery: Patient photographs compared with patient satisfaction ratings. *Plast Reconstr Surg*. 2012;129:253–262.
 92. Castello MF, Lazzeri D, Silvestri A, et al. Modified superficial musculoaponeurotic system face-lift: A review of 327 consecutive procedures and a patient satisfaction assessment. *Aesthetic Plast Surg*. 2011;35:147–155.
 93. Swanson E. Outcome analysis in 93 facial rejuvenation patients treated with a deep-plane face lift. *Plast Reconstr Surg*. 2011;127:823–834.
 94. Kamer FM, Frankel AS. SMAS rhytidectomy versus deep plane rhytidectomy: An objective comparison. *Plast Reconstr Surg*. 1998;102:878–881.
 95. Ivy EJ, Lorenc ZP, Aston SJ. Is there a difference? A prospective study comparing lateral and standard SMAS face lifts with extended SMAS and composite rhytidectomies. *Plast Reconstr Surg*. 1996;98:1135–1143; discussion 1144.
 96. Chang S, Pusic A, Rohrich RJ. A systematic review of comparison of efficacy and complication rates among face-lift techniques. *Plast Reconstr Surg*. 2011;127:423–433.
 97. Klassen AF, Cano SJ, Scott A, Snell L, Pusic AL. Measuring patient-reported outcomes in facial aesthetic patients: Development of the FACE-Q. *Facial Plast Surg*. 2010;26:303–309.
 98. Klassen AF, Cano SJ, Scott AM, Pusic AL. Measuring outcomes that matter to face-lift patients: Development and validation of FACE-Q appearance appraisal scales and adverse effects checklist for the lower face and neck. *Plast Reconstr Surg*. 2014;133:21–30.
 99. Panchapakesan V, Klassen AF, Cano SJ, Scott AM, Pusic AL. Development and psychometric evaluation of the FACE-Q Aging Appraisal Scale and Patient-Perceived Age Visual Analog Scale. *Aesthet Surg J*. 2013;33:1099–1109.
 100. Pusic A, Klassen A, Panchapakesan V, Cano S. Response to “The FACE-Q: The importance of full disclosure and sound methodology in outcomes studies”. *Aesthet Surg J*. 2014;34:628–631.
 101. Schwitzer JA, Klassen AF, Cano SJ, Pusic AL. Measuring outcomes that matter to cosmetic patients: Development and validation of the FACE-Q satisfaction with lips and lip lines scales (Abstract). *Plast Reconstr Surg*. 2014;134(4S-1):97.
 102. Schwitzer JA, Klassen AF, Cano SJ, Pusic AL. Measuring quality of life in facial aesthetic patients: Development and validation of the FACE-Q psychological function, social function, early life impact, and satisfaction with outcome and decision scales (Abstract). *Plast Reconstr Surg*. 2014;134(4S-1):96.
 103. Pusic AL, Klassen AF, Scott AM, Cano SJ. Development and psychometric evaluation of the FACE-Q satisfaction with appearance scale: A new patient-reported outcome instrument for facial aesthetics patients. *Clin Plast Surg*. 2013;40:249–260.